

# Lipoedema: from clinical presentation to therapy. A review of the literature

S.I. Langendoen, L. Habbema, T.E.C. Nijsten and H.A.M. Neumann

Department of Dermatology, Erasmus Medical Center, Postbus 2040, 3000 CA Rotterdam, the Netherlands

## Summary

### Correspondence

Sterre Langendoen.

E-mail: s.langendoen@erasmusmc.nl

### Accepted for publication

9 July 2009

### Key words

lipoedema, liposuction, pathophysiology, treatment

### Conflicts of interest

None declared.

DOI 10.1111/j.1365-2133.2009.09413.x

Lipoedema is an infrequently recognized disorder, first described by Allen and Hines in 1940. Lipoedema is characterized by bilateral enlargement of the legs due to abnormal depositions of subcutaneous fat associated with often mild oedema.<sup>1</sup> Different synonyms are found in the literature (Table 1), but because of the lack of a clear definition it is uncertain whether all publications in fact discuss lipoedema. This abundance of terminology and unclear definitions has resulted in confusion about lipoedema, underdiagnosis and mistreatment. For example, patients with lipoedema are often diagnosed and treated as if they had primary lymphoedema. Lipoedema is a chronic, progressive condition that may be associated with considerable morbidity. Initially, patients experience discomfort, easy bruising and tenderness of the disproportionately enlarged legs, which may progress to high-intensity pain and limited mobility. In addition to physical problems, lipoedema may be associated with psychological morbidity. Therefore, it is important that lipoedema is recognized as early as possible and that patients receive optimal information and care.

The objective of this review is to increase the awareness of physicians about lipoedema and to describe its clinical presentation, pathogenesis, management and therapies.

## Epidemiology

Although some authors state that lipoedema is a rare disease,<sup>2</sup> the majority feels that it is more frequent than expected and is often missed.<sup>3–6</sup> In one specialized lymphology clinic lipoedema was diagnosed in 15% of the patients referred,<sup>7</sup> and 10–15% of the patients of another oedema clinic were

Lipoedema is an infrequently recognized disorder in women. Lipoedema is characterized by bilateral enlargement of the legs due to abnormal depositions of subcutaneous fat associated with often mild oedema. There is substantial variability in disease severity. The diagnosis should be made as early as possible to prevent complications of the disorder, which is associated with increasing functional and cosmetic morbidity. This review describes clinical manifestations, pathogenesis, technical investigations, management and therapies of lipoedema, with the aim of optimizing management and care of patients with lipoedema.

diagnosed with lipoedema.<sup>8</sup> Although the incidence of lipoedema in the general population is not known, these two studies from specialty clinics support our suspicion that lipoedema is more common than most physicians realize. Epidemiological studies estimating the occurrence of lipoedema are warranted. Lipoedema occurs almost exclusively in women. To our knowledge, only two men with lipoedema have been reported in the literature.<sup>9,10</sup> Lipoedema most commonly starts during or soon after puberty. It has been suggested that in all women with increased fat deposits of the lower extremities, 60% is caused by obesity, 20% by lipoedema and 20% by a combination of both.<sup>7</sup> Although the proportion of women with a self-reported positive family history of lipoedema varies between 16% and 64%,<sup>1,5,8</sup> lipoedema is not included in the OMIM database for hereditary diseases (Online Mendelian Inheritance in Man, <http://www.ncbi.nlm.nih.gov/omim/>).

## Clinical presentation

Allen and Hines<sup>1</sup> described lipoedema as a clinical syndrome, characterized by the combination of subcutaneous deposition of fat in the buttocks and lower extremities and the accumulation of fluid in the legs. In 1951, Wold *et al.*<sup>9</sup> suggested the following diagnostic criteria: (i) occurrence almost exclusively in women; (ii) a bilateral and symmetrical nature with minimal involvement of the feet; (iii) minimal pitting oedema; (iv) pain, tenderness and easy bruising; and (v) persistent enlargement after elevation of the extremities or weight loss.

Patients complain of sensations of heaviness and discomfort of the legs, with moderate to severe sensitivity to digital pressure. The swelling and aching of lipoedema gets worse during

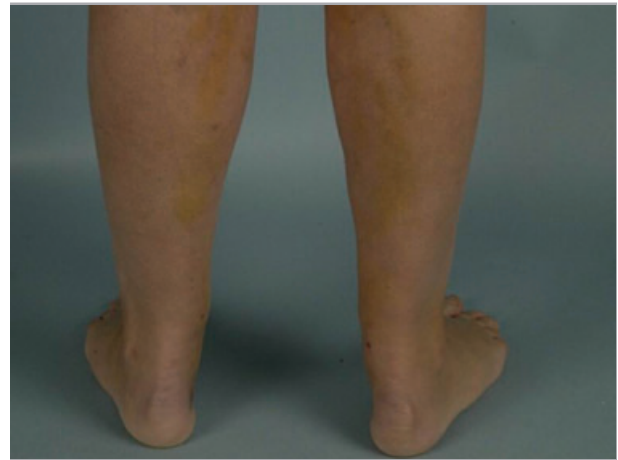
**Table 1** Different synonyms of lipoedema used in the literature. Because a clear definition is lacking, it is usually uncertain whether authors mean lipoedema, lipohypertrophy or obesity when using these terms

Focused on fat	
Adipocyanosis	
Adiposalgie	
Adipose segmentaire	
Adipositas (or adiposis) dolorosa	
Adipositas (or adiposis) oedematosa	
Adipositas spongiosa	
Fettbein	
Obésité inférieure	
Painful fat syndrome	
Zonale Adipositas	
Focused on oedema	
Oedema cyanotique des jambes	
Schmerzhaftes Lipödem	
Focused on morphology/descriptive	
Derkumkrankheit	
Lipohypertrophia corporis inferioris	
Rot-Dick-Schenkel	
Säulenbein	
Stovepipe legs	
Sülzbein	
Zonaler Riesenwuchs	

exercise and warm weather and does not recede with elevation of the legs, although a (usually mild) pitting oedema component will benefit from elevation. The oedema component becomes more prominent in time and is nonpitting but may become pitting to some extent at the end of the day.

The medical history of most patients shows that the majority has a history of dieting and exercising without any considerable benefit on the contours and complaints of the lower extremities. This adds to the psychological burden and low self-esteem of patients, which are risk factors for (increasing) obesity. Also, limited mobility due to embarrassment and/or discomfort, pain or mechanical hindrance may contribute to obesity in time. Limited mobility due to mechanical friction and skin irritation are well-known sequelae, even leading to inability to work. For many patients, it is impossible to wear ready-made clothes.

The symmetrical, bilateral fat deposits on the lower extremities develop slowly and gradually. Although about half of the patients may also be obese,<sup>7,9</sup> the enlargement of the lower extremities is disproportionate in relation to the trunk and upper extremities, face and neck. In early-stage lipoedema, the only sign can be the disappearance of the concave spaces on both sides of the Achilles tendon (filling of the retromalleolar sulcus) (Fig. 1). As the lipoedema progresses, the disorder becomes easier to recognize. Characteristically, the feet are spared and the fat deposits begin abruptly above the malleoli causing a sharp demarcation between normal and abnormal tissue at the ankle (cuff sign of lipoedema) (Fig. 2). The contours of the lower legs are described as 'stovepipe legs'. Patients in whom only the thigh is affected may show a less



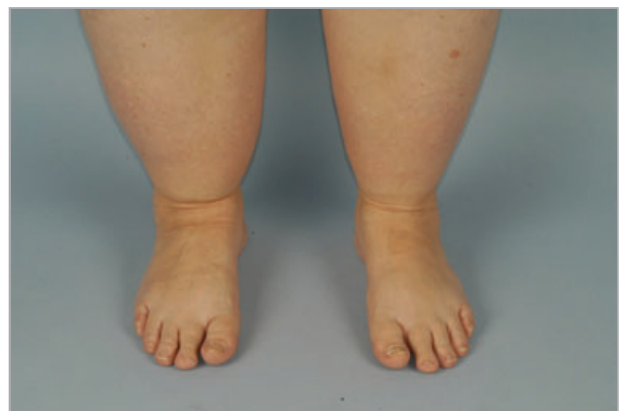**Fig 1.** Filling of the retromalleolar sulcus.

apparent cuff sign. In a number of patients, similar fat deposits exist in the upper extremities that end abruptly above the wrists, sparing the hands.

The course of lipoedema is variable. Some women develop minor lipoedema, which stabilizes and does not show progression over time. Other women show a gradual progression of the lipoedema, whereas in other patients an exacerbation is sometimes provoked by a stress situation such as pregnancy or surgery.<sup>11,12</sup>

## Historical classifications

Different phenotypes of lipoedema have been recognized. In addition to the first presentation described by Allen and Hines,<sup>1,9</sup> Moncorps *et al.*<sup>13</sup> described a subtype of lipoedema named the 'typus rusticanus' in 1940, nowadays known as 'type rusticanus Moncorps'. The difference between these groups is made clinically and is important because patients with the 'type rusticanus Moncorps' experience more serious complaints at a younger age, especially a dull spontaneous pain in the legs that is most prominent at the end of the day, which may resemble symptoms of chronic venous



**Fig 2.** 'Cuff sign' of lipoedema.

insufficiency in the absence of varicose veins.<sup>14</sup> The 'type rusticanus Moncorps' is associated with erythrocyanosis crurum puellarum (i.e. cyanotic, bluish discoloration of the lower third of the legs), cinnabar spots (i.e. bright red hyperaemic spots) and follicular hyperkeratosis. It has been hypothesized<sup>14,15</sup> that there is an intrinsic connective tissue defect of the skin of these patients, clinically visualized as stretch marks, after a skin elasticity deficit of the skin of the calf was observed. Furthermore, the frequent presence of knock knees, flat feet and moderately impaired calf muscle pump function (venous return), that may be due to musculofascial insufficiency (i.e. relatively weak connective tissue of the fascial compartment), might even point to a more generalized connective tissue defect.<sup>14</sup> Nowadays, the 'type rusticanus Moncorps' is called erythrocyanosis crurum puellarum, as described by Klingmüller in 1921, and is seen as a variation of acrocyanosis in combination with fat legs, but without oedema.<sup>16</sup> Schmitz<sup>17</sup> described three variants of lipoedema including the type rusticanus Moncorps and two patient groups with varicose veins (i.e. obese women with disproportionate fat deposits on the lower extremities and varicose veins, and slim women with disproportionately fat legs who also frequently have varicose veins). Three different shapes in the legs (upper leg type, lower leg type, ankle type) and two shapes in the arms (upper and lower arm type) were mentioned by Herpertz.<sup>7</sup> Meier-Vollrath and Schmeller<sup>18</sup> described three stages of lipoedema. In stage I, the skin looks flat, but the subcutis is enlarged and, when palpating the skin, feels like 'styrofoam balls in a plastic bag'. In stage II (Fig. 3), walnut- to apple-like indurations may develop and the overlying skin has an irregular appearance ('mattress phenomenon'). Stage III shows bigger indurations and deforming fat deposits (Fig. 4). The authors also suggested a classification according to the location of the fat deposits: mainly buttocks (type I), buttocks to knees (type II), buttocks to malleoli (type III), mainly arms (type IV) and mainly lower legs (type V).<sup>18</sup> These regional classifications are developed mainly for therapeutic follow-up purposes and are not based on pathophysiological knowledge.

### Differential diagnosis

Lipoedema has a distinct clinical presentation, and for physicians familiar with the disease the diagnosis can be made by patient history and clinical examination. There is no pathognomonic diagnostic test for lipoedema. The most relevant differential diagnosis of lipoedema (Table 2) includes obesity, lipohypertrophy and lymphoedema. Further elaboration of the causes of oedema of the lower legs (chronic venous insufficiency, idiopathic cyclic oedema, oedema due to internal disease, and orthostatic oedema) which usually concerns pitting oedema, is beyond the scope of this review.

In obesity, the increase of subcutaneous fat deposits is generalized and not disproportionate. Furthermore, the typical sparing of the feet and the pain of lipoedema are lacking. Herpertz<sup>7</sup> described lipohypertrophy as increased symmetrical

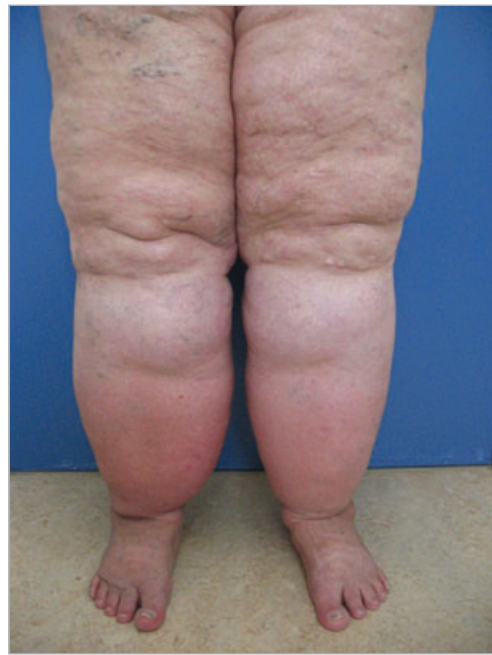

Fig 3. Lipoedema stage II.

subcutaneous fat deposits, mostly on the legs and arms in women. According to Herpertz,<sup>7</sup> lipoedema is always preceded by lipohypertrophy. The difference between lipohypertrophy and lipoedema is the absence of oedema and pain in lipohypertrophy. The term 'lipodystrophy' is reserved for local

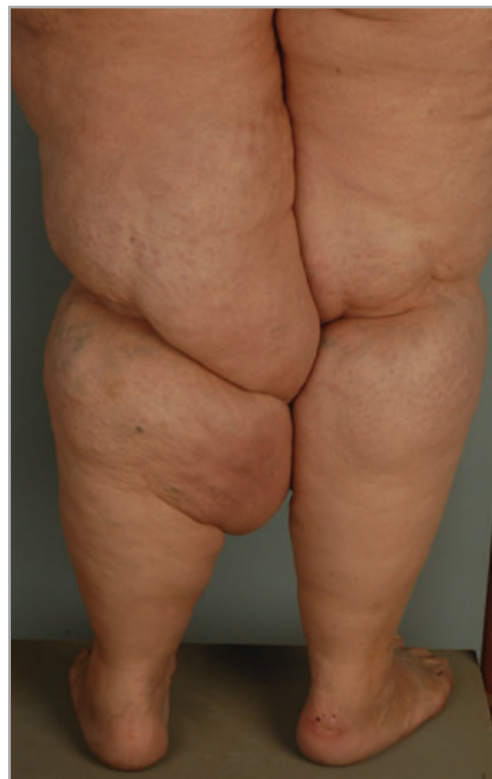

Fig 4. Lipoedema stage III.

Table 2 Differential diagnosis of lipoedema

	Lipoedema	Obesity	Lipohypertropy	Lymphoedema
Patient history				
Sex	Female	Male and female	Female	Male and female
Family history positive	Common	Common	Possible	Present in primary lymphoedema
Proven hereditary factor	Absent	Absent	Absent	Present in primary lymphoedema
History of erysipelas	Absent	Absent	Absent	Usually present
Progression	Involved areas	All over body, although in most men (and some women) limited to trunk	Not progressive	Proximally, from distal portion of limb
Response to diet	None	Excellent	None	None
Effect of elevation (oedema reduction)	Minimal (limited to pitting oedema component)	Ineffective	Ineffective	Effective initially
Physical examination				
Bilateral involvement	Always	Always	Always	Primary: often; secondary: rare
Foot involvement	Absent	Common	Absent	Common
Malleolar fat pad	Present	Absent	Absent	Absent
Consistency on palpation	Soft-firm	Soft	Soft	Firm
Pitting oedema	Minimal	Absent	Absent	Always present in variable severity
Pain on pressure	Common	Absent	Absent	Absent

damaged subcutaneous fat (e.g. insulin injections in patients with diabetes, or local trauma).

Lipoedema can be differentiated from chronic venous insufficiency because chronic venous insufficiency is associated with hyperpigmentation, ankle flare and pitting oedema that is minimal after bed rest. Moreover, in lipoedema the symptoms increase with exercise, in contrast to chronic venous insufficiency [provided that medical elastic compression stockings (MECS) are worn during exercise]. In contrast to lymphoedema, Stemmer's sign (i.e. the inability to pinch a fold of skin at the base of the second toe due to thickening of the skin and subcutaneous tissues) is negative, and lipoedema is always symmetrical.

## Pathophysiology

The aetiology of lipoedema is still unknown, and some authors consider it a physiological variant. The two main components of lipoedema, consisting of enlargement of the subcutaneous fatty tissue in combination with the formation of oedema, have been studied but are still not well understood. Histopathology of biopsies and liposuction aspirate does not show any abnormalities, except for oedema of the fat cells and/or interstitium.<sup>4,7,8,10,19,20</sup>

Fat tissue consists of fat lobes (i.e. collection of fat cells), surrounded by connective tissue septa in which free nerve fibres, arterioles, venules and lymphatic vessels are located. Water may collect in fat tissue by swelling of the fat cells and/or collecting interstitial fluid, thereby producing an

oedematous state of the fat tissue. In healthy fat, the amount of interstitial space is much less than in many other tissues (about 10% of its total volume, whereas in many tissues it exceeds 20%).<sup>21</sup> In lipoedema, the anatomy of the lymphatic vessel system has been found to be normal, as far as the large lymph vessels are concerned. However, the increased intercellular pressure due to expanding fat tissue (because of disproportionate enlargement of the adipocytes) may cause slight mechanical obstruction of the small lymphatic vessels in the septa, which results in mild lymphostasis and oedema of the subcutaneous tissue. Photoplethysmography and quantitative lymphoscintigraphic studies showed that mild venous and lymphatic insufficiency, respectively, may be present, as compared with healthy controls. However, the degree of insufficiency never reached the level of true chronic venous insufficiency or lymphoedema, and large lymph vessels were normal and sufficient.<sup>4,5,22–24</sup> Others found that in lipoedema in the early stages the lymph flow in some cases was reduced, but in others increased. It was found that lymph transport in lipoedema decreases as the body ages and the fibrosis increases.<sup>25,26</sup> In long-standing lipoedema, small alterations of the lymphatic tissue may appear, which can be visualized by indirect lymphography. In lipoedema, the injection depots look flame-like, unlike the usually visualized round deposits. The 'tongues of flame' are likely to represent distended pre-lymphatic spaces.<sup>7,22,27–31</sup> Some investigators found enlarged and obliterated lymphatic microvessels,<sup>29</sup> lymphatic collectors following a tortuous course through the fatty subcutaneous tissue<sup>22,29</sup> and multiple microlymphatic aneurysms of lymphatic

tic capillaries in patients with lipoedema,<sup>30</sup> of which the pathophysiological role remains to be established.

The relationship between lymphatics and adipose tissue remains controversial. Because a relationship between the size of fat lobules and the relative richness of blood supply and lymphatic drainage was found (a slow flow rate and stagnation of lymphatic drainage enhance the deposition of fat),<sup>21,32</sup> the mechanism of lipoedema might be a continuing deterioration in which the growing adipocytes keep slowing the lymphatic drainage, while it is still unclear whether the primary factor is the growing adipocyte or an intrinsic problem in the interstitial space or microlymphatic pathway. Compression of the nerve fibres in the septa may also explain the complaints of discomfort and, in later stages, pain. Although this is an attractive theory, it cannot fully explain the pathogenesis of lipoedema. Moreover, in other conditions with comparable or even more enlarged fat deposits, such as lipohypertrophy or adiposis, there is no reduction of the lymphatic flow.

## Investigations

As varicose veins are invisible in the thick adipose tissue and lipoedema can be present concomitantly with venous disease, duplex ultrasound is indicated if complaints cannot fully be explained by lipoedema. Dynamic lymphoscintigraphy is a good tool to rule out true lymphoedema. Imaging studies using computed tomography, magnetic resonance imaging and/or ultrasound showed that the oedema is minimal and that limb swelling is due entirely to bilateral homogeneous enlargement of the subcutaneous compartment in the early stages of lipoedema.<sup>33–38</sup> Because there are no diagnostic and therapeutic implications of these investigations, we consider them not indicated in patients with lipoedema.

## Therapy

### Patient education

Most patients are relieved by the fact that their complaints and appearance are caused by a disease instead of a lack of self-control. This is, however, followed by disappointment because there is no easy solution to their problems. Acknowledgment of the severity of the complaints and optimal information and education about lipoedema are essential in the management of patients with lipoedema. Psychological counselling may be indicated for some patients.

### Weight control

People with lipoedema do not inherently have obesity, but about 50% are overweight.<sup>39</sup> Prevention of obesity is important, because the additional weight gain of the body areas affected by lipoedema is very resistant to dieting and exercise. Therefore, weight loss will not improve patients' discomfort and appearance, resulting in frustration and demotivation, which may enhance the development of obesity.<sup>40–42</sup> Because

of the disproportionate enlargement of the lower extremities, the body mass index and total body weight are suboptimal obesity parameters in patients with lipoedema. We advise our patients to use their waist circumference as an indicator for their 'healthy' weight. Cut-off points for categorization of waist circumference are ethnicity dependent.<sup>43</sup> Based on the recommendations of the World Health Organisation and Health Council of the Netherlands,<sup>44</sup> women with a waist circumference of < 80 cm are categorized as normal, 80–87.9 cm as overweight and > 88 cm as obese. Diet recommendations are therefore focused on achieving the desired waist circumference and avoiding daily variation in calorie intake.

### Conservative therapy

A combination of manual lymphatic drainage therapy and compression therapy ('complex physical decongestion therapy')<sup>7,11,14,41,45</sup> is widely accepted as standard therapy. However, good clinical evidence is lacking. Compression therapy may improve, in part, the symptoms of lipoedema and prevent the progression of the lymphatic component of lipoedema. Patients with concomitant chronic venous insufficiency and/or lymphoedema have an additional indication for compression therapy. Patients with the 'type rusticus Moncorps' may also benefit from compression therapy, probably because of correction of the moderately impaired calf muscle pump function. For some patients with lipoedema, wearing MECS is too painful.<sup>7</sup> Diuretics<sup>7,20,46</sup> and limb elevation have unsatisfactory results in patients with lipoedema,<sup>5,7</sup> although the oedema component will benefit from elevation. Disturbed walking patterns caused by orthopaedic problems (such as flat feet) or mechanical hindrance by the enlarged fat deposits (mainly on the medial thighs) should be treated if possible.

### Surgery

Surgical debulking procedures or liposuction under general anaesthesia without massive subcutaneous infiltration of the excessive fat depots<sup>19,45</sup> are contraindicated because of the risk of iatrogenic damage to the lymphatics.<sup>40</sup> For some authors, lipoedema is a (relative) contraindication for surgery of varicose veins because it may worsen lipoedema and may be associated with complications such as delayed wound healing and postoperative swelling.<sup>11,42,47</sup> It might be advisable not to risk exacerbation of lipoedema by performing surgery on these patients, but instead prevent progression of chronic venous insufficiency and/or lymphoedema by adequate compression therapy.

The introduction of tumescent local anaesthesia in the 1980s has greatly changed the therapeutic options for lipoedema.<sup>48</sup> In tumescent local anaesthesia, large amounts of fluid (containing saline, lidocaine, sodium bicarbonate and adrenaline) are infiltrated in the subcutaneous tissues. Tumescent liposuction is at least as effective as the conventional ('dry') liposuction and the so-called 'wet' liposuction in removing adipose aspirates, but has the advantage that it is

significantly less likely to damage the lymphatic vessels.<sup>12</sup> The use of vibrating microcannulas further improved the results in patients with lipoedema.

Although tumescent liposuction cannot cure lipoedema, results are promising: especially an impressive improvement of pain is reported by patients with lipoedema.<sup>49</sup> Furthermore, functional improvement in mobility is noted. A recent case series of patients with lipoedema demonstrated that this technique improved appearance and quality of life and reduced symptoms such as tendency to swelling and pain.<sup>2,18</sup> Another group reported follow-up periods of more than 8 years without complications or negative results.<sup>50</sup> Because often extensive amounts of adipose tissue have to be removed, multiple sessions are necessary, thereby making it a time-consuming method. Ideally it is performed relatively early to prevent progression of the disorder.<sup>51</sup> The German Phlebological Society recommends liposuction as part of the therapeutic armamentarium in the management of lipoedema.<sup>52</sup> Unfortunately, this therapy is usually not supported by health insurance companies.

## Conclusion

Because lipoedema is a relatively frequent, chronic disorder with considerable morbidity, the diagnosis should be made as early as possible to inform patients and, hopefully, prevent progression. The diagnosis is based on patient history and physical examination. Duplex ultrasound and/or dynamic lymphoscintigraphy are indicated if complaints cannot fully be explained by lipoedema. The aim of our treatment is to prevent or reduce obesity, to optimize patient mobility, reduce complaints and to improve overall quality of life. The importance of weight control is emphasized in all patients. Conservative therapy such as manual lymphatic drainage, MECS and orthopaedic or psychological counselling is started on indication. For patients with acceptable waist circumference, the treatment of choice is tumescent liposuction, which is at this moment the only available technique to correct the abnormal adipose tissue.

## References

- Allen EV, Hines EA. Lipedema of the legs: a syndrome characterized by fat legs and orthostatic edema. *Proc Staff Meet Mayo Clin* 1940; **15**:184–7.
- Schmeller W, Meier-Vollrath I. Tumescent liposuction: a new and successful therapy for lipedema. *J Cutan Med Surg* 2006; **10**: 7–10.
- Beninson J, Edelglass JW. Lipedema – the non-lymphatic masquerader. *Angiology* 1984; **35**:506–10.
- Bilancini S, Lucchi M, Tucci S *et al.* Functional lymphatic alterations in patients suffering from lipedema. *Angiology* 1995; **46**:333–9.
- Harwood CA, Bull RH, Evans J, Mortimer PS. Lymphatic and venous function in lipoedema. *Br J Dermatol* 1996; **134**:1–6.
- Fonder MA, Loveless JW, Lazarus GS. Lipedema, a frequently unrecognized problem. *J Am Acad Dermatol* 2007; **57**:S1–3.
- Herpertz U. [Lipedema]. *Z Lymphol* 1995; **19**: 1–11.
- Gregl A. [Lipedema]. *Z Lymphol* 1987; **11**: 41–3.
- Wold LE, Hines EA Jr, Allen EV. Lipedema of the legs; a syndrome characterized by fat legs and edema. *Ann Intern Med* 1951; **34**:1243–50.
- Chen SG, Hsu SD, Chen TM *et al.* Painful fat syndrome in a male patient. *Br J Plast Surg* 2004; **57**:282–6.
- Földi M, Idiazabal G. The role of operative management of varicose veins in patients with lymphedema and/or lipedema of the legs. *Lymphology* 2000; **33**:167–71.
- Hoffmann JN, Fertmann JP, Baumeister RGH *et al.* Tumescent and dry liposuction of lower extremities: differences in lymph vessel injury. *Plast Reconstr Surg* 2003; **113**:718–24.
- Moncorps C, Brinkhaus G, Herfeld-Münster F. [Experimental investigations in acrocyanosis]. *Arch Dermatol Syph* 1940; **180**:209–15.
- Jagtman BA, Kuiper JP, Brakkee AJ. [Lipedema of the legs]. *Ned Tijdschr Geneesk* 1987; **131**:345–8.
- Jagtman BA, Kuiper JP, Brakkee AJM. [Measurements of skin elasticity in patients with lipedema of the Moncorps ‘rusticanus’ type]. *Phlebologie* 1984; **37**:315–19.
- Braun-Falco O, Wolff HH, Plewig G *et al.* Erythrocytosis crurum puellarum. In: *Dermatologie und Venerologie* (Braun-Falco O, Wolff HH, Plewig G, Landthaler M, Burgdorf WHC, eds), 5th edn. Heidelberg: Springer Medizin Verlag, 2005; 773.
- Schmitz R. [Lipedema from the differential diagnostic and therapeutic viewpoint]. *Z Hautkr* 1987; **62**:146–57.
- Meier-Vollrath I, Schmeller W. [Lipoedema—current status, new perspectives]. *J Dtsch Dermatol Ges* 2004; **2**:181–6.
- Stallworth JM, Hennigar GR, Jonsson HT *et al.* The chronically swollen painful extremity. *JAMA* 1974; **228**:1656–9.
- Rudkin GH, Miller TA. Lipedema: a clinical entity distinct from lymphedema. *Plast Reconstr Surg* 1994; **94**:841–7.
- Ryan T. Lymphatics and adipose tissue. *Clin Dermatol* 1995; **13**:493–8.
- Weissleder H, Brauer JW, Schuchhardt C *et al.* [Value of functional lymphoscintigraphy and indirect lymphangiography in lipedema syndrome]. *Z Lymphol* 1995; **19**:38–41.
- Boursier V, Pecking A, Vignes S. [Comparative analysis of lymphoscintigraphy between lipedema and lower limb lymphedema]. *J Mal Vasc* 2004; **29**:257–61.
- van Geest AJ, Esten SCAM, Cambier J-PRA *et al.* Lymphatic disturbances in lipedema. *Phlebologie* 2003; **32**:138–42.
- Brauer WJ, Brauer VS. Altersabhängigkeit des Lymphtransportes beim Lipödem und Lipolymphödem. *LymphForsch* 2005; **9**:6–9.
- Brauer WJ, Weissleder H. Methodik und Ergebnisse der Funktionslymphszintigraphie: Erfahrungen bei 924 Patienten. *Phlebologie* 2002; **31**:118–25.
- Partsch H, Stoberl C, Urbanek A *et al.* Clinical use of indirect lymphography in different forms of leg edema. *Lymphology* 1988; **21**:152–60.
- Tiedjen KU, Heimann KD, Tiedjen-Kraft U *et al.* Indirect xero-lymphography in lymphedema, lipedema and venous insufficiency. *Phlebologie* 1992; **92**:396–8.
- Bollinger A. Microlymphatics of human skin. *Int J Microcirc Clin Exp* 1993; **12**:1–15.
- Amann-Vesti BR, Franzeck UK, Bollinger A. Microlymphatic aneurysms in patients with lipedema. *Lymphology* 2001; **34**:170–5.
- Stoberl C, Partsch H, Wruhs M. [Diagnostic value and assessment criteria of indirect lymphography in lymphedema]. *Vasa* 1990; **19**:212–17.
- Földi E, Földi M, Tischendorf F. [Adipositas, lipedema and lymphostasis]. *Med Welt* 1983; **34**:198–200.
- Hadjis NS, Carr DH, Banks L *et al.* The role of CT in the diagnosis of primary lymphedema of the lower limb. *AJR Am J Roentgenol* 1985; **144**:361–4.

- 34 Vaughan BF. CT of swollen legs. *Clin Radiol* 1990; **41**:24–30.
- 35 Monnin-Delhom ED, Gallix BP, Achard C *et al.* High resolution unenhanced computed tomography in patients with swollen legs. *Lymphology* 2002; **35**:121–8.
- 36 Duewell S, Hagspiel KD, Zuber J *et al.* Swollen lower extremity: role of MR imaging. *Radiology* 1992; **184**:227–31.
- 37 Werner GT, Rodiek SO. [Value of nuclear magnetic resonance tomography in leg edema of unknown origin. Preliminary report]. *Z Lymphol* 1993; **17**:2–5.
- 38 Dimakakos PB, Stefanopoulos T, Antoniadis P *et al.* MRI and ultrasonographic findings in the investigation of lymphedema and lipoedema. *Int Surg* 1997; **82**:411–16.
- 39 Greer KE. Lipedema of the legs. *Cutis* 1974; **14**:89.
- 40 Stiefelhagen P. [No lymphedema, no obesity. How can lipedema be treated?]. *MMW Fortschr Med* 2001; **143**:15.
- 41 Macdonald JM, Sims N, Mayrovitz HN. Lymphedema, lipedema and the open wound: the role of compression therapy. *Surg Clin North Am* 2003; **83**:639–58.
- 42 Brunner U. [Vascular diseases in lipedema of the legs. Special symptoms, common therapeutic results, viewpoint on vascular surgery]. *Schweiz Med Wochenschr* 1982; **112**:1130–7.
- 43 Zhu S, Heshka S, Wang Z *et al.* Combination of BMI and waist circumference for identifying cardiovascular risk factors in whites. *Obes Res* 2004; **12**:633–45.
- 44 Health Council of the Netherlands. [Advisory Report on Excess Weight and Obesity]. The Hague: Health Council of the Netherlands, 2003.
- 45 Rank BK, Wong GSC. Lipoedema. *Aust NZ J Surg* 1966; **35**:165–9.
- 46 Wienert V, Leeman S. [Lipedema]. *Hautarzt* 1991; **42**:484–6.
- 47 Pereira de Godoy JM, de Fatima Guerreiro Godoy M, Hayashida M. Lipoedema and varicose vein surgery: a worse prognosis? *Acta Angiol* 2005; **11**:186–7.
- 48 Klein JA. The tumescent technique: anesthesia and modified liposuction technique. *Dermatol Clin* 1990; **8**:425–37.
- 49 Schmeller W, Meier-Vollrath I. [Successful surgical therapy of lipedema by liposuction]. *Phlebologie* 2004; **33**:23–9.
- 50 Rapprich S, Loehnert M, Hagedorn M. Therapy of lipoedema syndrome by liposuction under tumescent local anaesthesia. *Ann Dermatol Venerol* 2002; **129**:1S711.
- 51 Sattler G, Bergfeld D, Sommer B. [Liposuction]. *Hautarzt* 2004; **55**:599–604.
- 52 Wienert V, Földi E, Schmeller W *et al.* [Guideline: lipedema of the legs]. *Phlebologie* 2005; **34**:42–4.